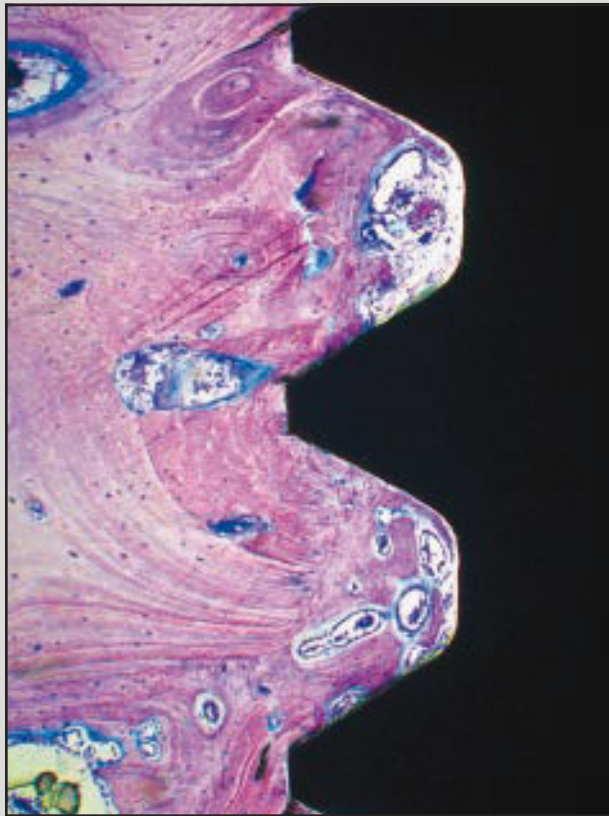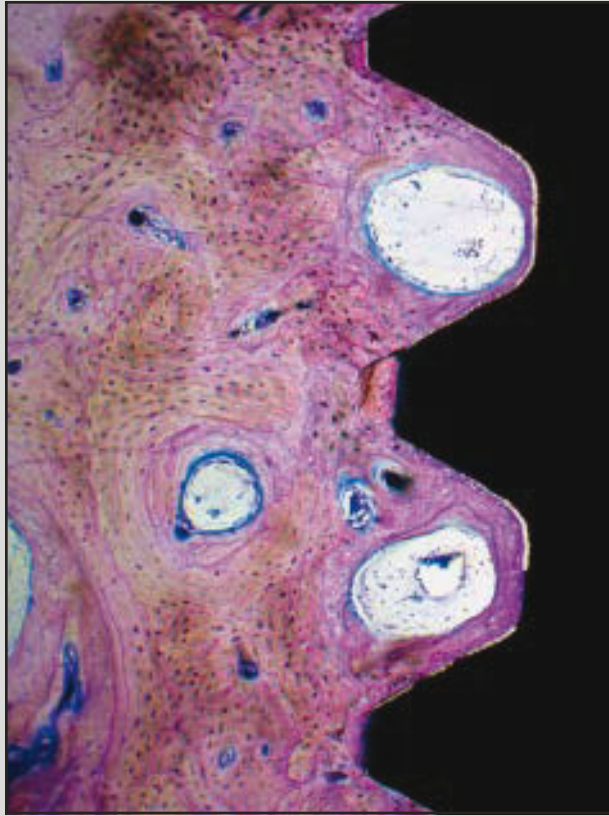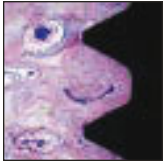


Early Bone Formation Adjacent to Oxidized and Machined Implant Surfaces: A Histologic Study



Massimo Simion, MD, DDS¹
(Produced only the histology for this study.)
Marco Benigni, DDS, PhD²
Khalid Al Hezaimi, DDS, MSc³
David M. Kim, DDS, DMSc⁴

Various designs of dental implants representing different geometries and surface technologies are commercially available for patient treatment. However, data with regard to the biologic events that occur immediately after implant placement, regardless of the surface characteristic, are scarce. It has become a common procedure to perform immediate/early prosthetic loading rather than delayed loading. The goal of this study was to observe the early biologic events of peri-implant healing to understand the role of surface modifications in relation to the early phases of bone integration. The secondary goal was to observe the possible differences in the healing pattern at two oral implant surfaces differing in morphology and roughness (R_a), with R_a values ranging from 0.5 μm (machined surface; MS) to 1.5 μm (oxidized surface; OS). A total of 36 implants were placed in six foxhound dogs, equally divided between machined and oxidized surfaces. Three implants were positioned per hemimandible following a randomization scheme. Each animal was euthanized at a specific time point for histologic observation and histomorphometry: immediately after implant insertion and after 24 hours, 7 days, 15 days, 30 days, and 90 days. The study demonstrated an extremely low bone-implant contact (BIC) for both OS and MS implant surfaces during the first 15 days after implant placement (ranging from 12.9% to 26.9% independent of the implant surface). Increased BIC values were observed only in the 30- and 90-day specimens. The presence and the degradation of residual bone particles acted as centers for new bone formation, with osteoblasts lining osteoid tissue and subsequently woven bone independent of the implant surface characteristics. The bone-forming activity appeared strongly reduced after 30 days of healing and seemed to be complete only in the 90-day specimens, where abundant lamellar bone was evident. There is a continuing effort to develop improved titanium surfaces to achieve more rapid osseointegration and improve BIC, with the ultimate goal of applying occlusal load as early as possible. Since immediate or early implant loading is applied during and not after the first 15 days, the findings in the present study of an extremely low BIC and limited mineralized bone formation for both implant surfaces during the first 15 days after implant placement suggest that the surface roughness may not be a key factor for successful osseointegration of immediately or early loaded implants. Within the limits of this study, it can be stated that osseointegration follows a similar healing pattern with machined and oxidized implant surfaces. (Int J Periodontics Restorative Dent 2015;35:9–17. doi: 10.11607/prd.2217)

¹Professor and Chairman, Department of Periodontology, University of Milan, Maxillofacial and Odontostomatology Unit, Fondazione Cà Granda IRCCS Ospedale Maggiore Policlinico, Milan, Italy; Co-chairman of Eng. A. B. Growth Factors and Bone Regeneration Research Chair, King Saud University, Riyadh, Saudi Arabia.

²Researcher, Maxillofacial and Odontostomatology Unit, Fondazione Cà Granda IRCCS Ospedale Maggiore Policlinico, Milan, Italy.

³Chairman and Associate Professor, Eng. A.B. Growth Factors and Bone Regeneration Research Chair, Department of Periodontics and Community Dentistry, College of Dentistry, King Saud University, Riyadh, Saudi Arabia.

⁴Associate Professor, Division of Periodontology, Department of Oral Medicine, Infection, and Immunity, Harvard School of Dental Medicine, Boston, Massachusetts, USA.

Correspondence to: Dr David M. Kim, Harvard School of Dental Medicine, 188 Longwood Avenue, Boston, Massachusetts 02115, USA; fax: 617-432-1897; email: dkim@hsdm.harvard.edu.

©2015 by Quintessence Publishing Co Inc.

The treatment of partial and totally edentulous patients with dental implants is a predictable and recommended therapy in contemporary dentistry. Various designs of dental implants representing different geometries and surface technologies are commercially available for patient treatment. However, data with regard to bone tissue responses and stability for comparison of their biologic performance are scarce.¹




Fig 1 Scanning electron microscope images of the two implant surfaces investigated in the study. (a) Oxidized surface. (b) Machined surface. Magnification $\times 500$.

The highly complex multicellular process of osseointegration, including the osteoblast activity at the bone surface of the insertion site or within new bone forming as part of the wound healing response, may be assessed solely through in vivo studies. In vitro experiments simplify the healing process and disregard the biologic aspects of osseointegration, making it difficult to define the true influence that alterations in surface parameters have in a clinical situation. The use of an in vivo model of osseointegration is therefore a key component in determining the potential clinical benefits of surface modification of titanium and titanium alloy implants.²

It has been suggested that moderately rough implant surfaces (roughness [R_a] of 1 to 1.5 μm) may accelerate and increase bone apposition at the bone-implant interface.³ This would present a major advantage when an immediate prosthetic load is applied. However, some studies reported an augmented risk of peri-implant tissue infection and progressive bone loss for these surfaces.⁴⁻⁶

Knowledge of the biologic events that occur immediately after implant placement, regardless of surface characteristics, is key to understanding the role played by the host tissues during the initial healing process. It has become common to perform immediate/early prosthetic loading rather than staged loading. Limited in vivo information exists regarding the early biologic events that occur at the bone-implant interface when implants with different surfaces are positioned in healed ridges.

The main objective of this study was to monitor the early biologic events (from baseline to 90 days postoperatively) of peri-implant healing and to understand the role of surface modifications in the early phases of bone integration, relating this to a better understanding of the osseointegration process. The secondary goal was to observe the possible differences in the healing pattern of osseointegration at two oral implant surfaces differing in morphology and roughness with R_a values ranging from 0.5 μm (machined surface; MS) to 1.5 μm (oxidized surface; OS).

Method and materials

The experimental protocol was approved by the Institutional Animal Care and Use Committee at the College of Dentistry, King Saud University, Riyadh, Saudi Arabia.

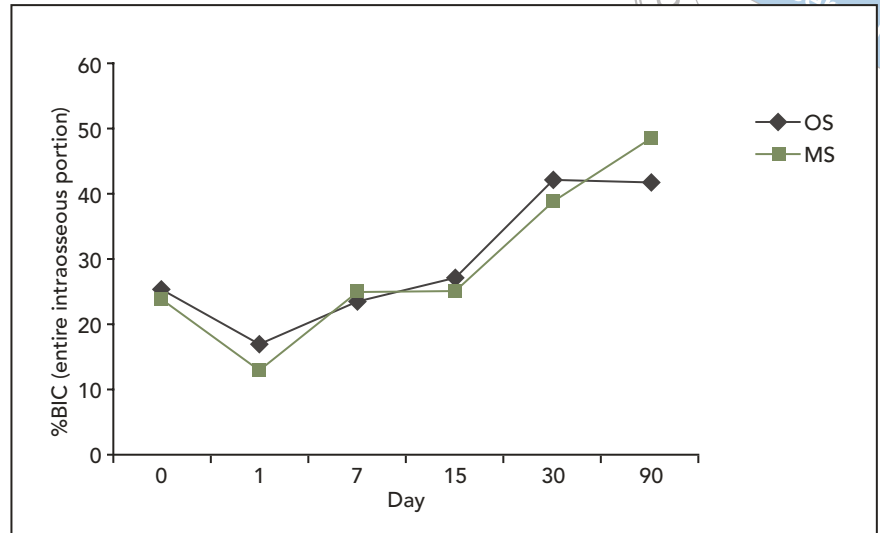
A total of six foxhound dogs (25 kg) were included in the study. The experiment and the surgery were performed at the King Saud University of Riad. The animals were euthanized at a specific time point: immediately after implant insertion and after 24 hours, 7 days, 15 days, 30 days, and 90 days.

Implants

A total of 36 implants (iMAXpro, iMAX3) were included in the study, six for each animal.

All implants were manufactured from grade 4 commercially pure titanium (cpTi). The surfaces of 18 implants were roughened by an oxidizing process (OS) (Fig 1a), and the remaining 18 implants were left with an MS (Fig 1b). All implants were decontaminated through a plasma cleaning system and sterilized by

Fig 2 Degree of osseointegration shown in percentage of bone-implant contact (%BIC) from day 0 to 90 at the oxidized surface (OS) and machined surface (MS) implants.



gamma radiation. The implants were 3.30 mm in diameter and 10 mm in length with a slightly conical shape and a tapered apical portion.

Surgical procedure

The mandibular premolars and first molars were extracted prior to implant placement. Three months after tooth extraction, implant insertion surgery was performed.

After achieving general and local anesthesia, a crestal incision was made to reflect the mucoperiosteal flaps. Implant placement was performed following the standard guidelines, positioning the implant platform at the osseous crest level. Three implants were placed following a randomization scheme per hemimandible. All implants were allowed to protrude a half millimeter above the bone level to avoid excessive compression of the cortical bone. Size-matched, 3-mm-height healing abutments were placed,

and the flaps were sutured with nonresorbable polytetrafluoroethylene sutures (Cytoplast, Osteogenics Biomedical), which were removed after 10 days. Healing abutments were not submerged and were not in occlusal contact. The animals were provided the standard post-surgical infection control by administration of amoxicillin 500 mg twice daily for 10 days. They were kept on a soft food diet throughout the study.

Histologic processing

The specimens were fixated by immersion in 10% buffered formaldehyde. Dehydration of the specimens was accomplished by increasing ethanol concentrations using a dehydration system with agitation and vacuum. The samples were embedded in Technovit 7200 VLC resin (Heraeus Kulzer) and sliced longitudinally on an Exakt cutting unit (Exakt). The slices were reduced by

microgrinding and polishing using an Exakt grinding unit to an even thickness of 30 to 40 μm . These were stained with toluidine blue/pyronin G and examined using an Eclipse E1000M light microscope (Nikon).

Histomorphometric analysis

Digital pictures of each sample at $\times 4$ magnification were obtained with a microscope (Eclipse 50i, Nikon) and a digital camera (Digital Sight DS-Fi1, Nikon). The pictures were uploaded to specialized software (NIS Elements 3.2, Nikon) and histomorphometrically analyzed to calculate the bone-implant contact (BIC) on the total length of the implants.

Results

The degree of osseointegration, expressed in percentage BIC (%BIC), from day 0 to 90 is summarized in Fig 2.



Fig 3 Histologic images of two specimens at day 0 (original magnification $\times 2$). The low bone-implant contact is mainly limited to the most coronal portion of the implant engaged in the cortical bone. (left) Oxidized surface. (right) Machined surface.

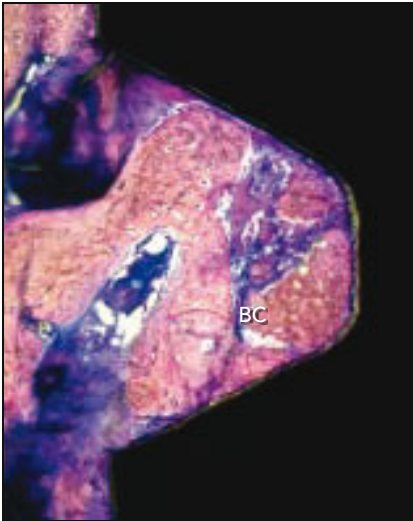

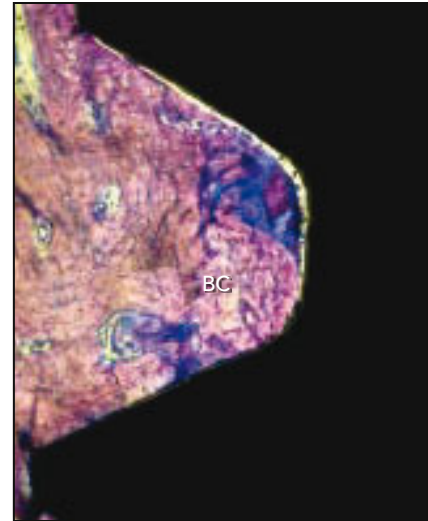


Fig 4 Higher magnification of histologic specimens at day 0 (original magnification $\times 20$). Residual bone chips (BC) are visible between the implant threads in the two implant samples. (left) Oxidized surface. (right) Machined surface.



Clinical results

One dog was euthanized immediately after implant placement. The other five dogs recovered well after the surgery and showed uneventful healing for the corresponding time lapse.

At the 3-month observation, some of the implant sites demonstrated different degrees of plaque

accumulation and peri-implant tissue inflammation.

Histologic results

Day 0 observation

Both OS and MS implants showed extremely low BIC (25.5% and 23.9%, respectively), mainly limited to the most coronal portion of the

implant engaged in the cortical bone and at the tips of the implant threads (Fig 3).

The areas with no contact were mainly filled with blood clot and various amounts of bone chips derived from bone drilling and implant insertion (Fig 4). No signs of bone-forming activity were evident in any of the specimens.

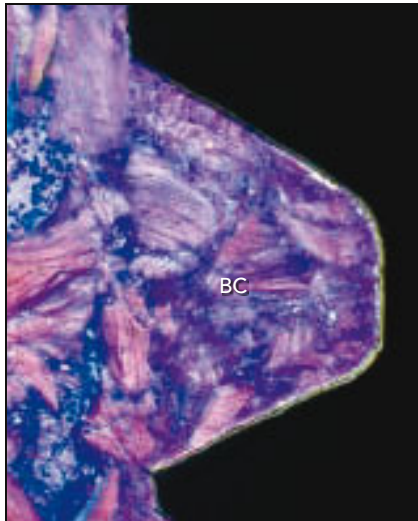


Fig 5 Histologic specimens at day 1 (original magnification $\times 20$). Most of the space between the implant threads is filled with coagulum, and no signs of new bone formation are visible. BC = bone chips. (left) Oxidized surface. (right) Machined surface.

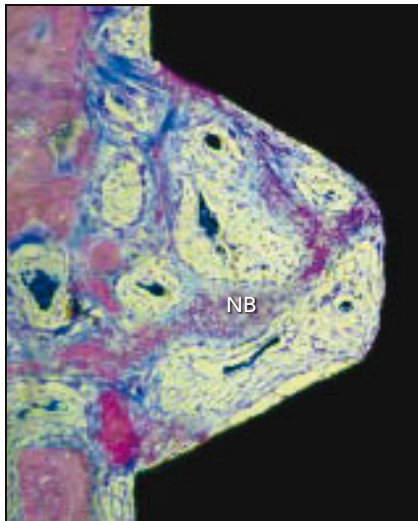
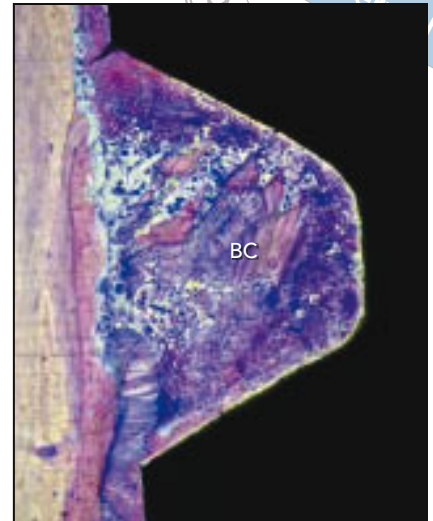
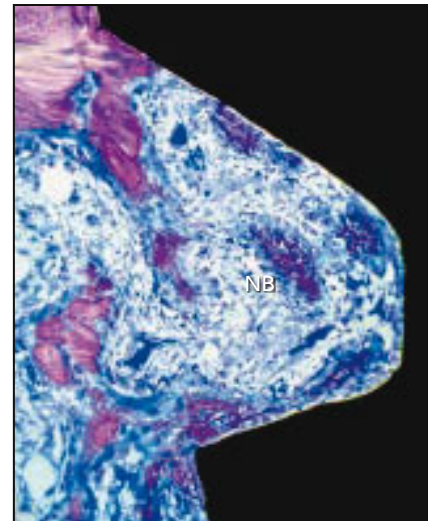


Fig 6 Histologic specimens at day 7 (original magnification $\times 20$). Active resorption of the bone chips and consecutive new bone (NB) formation is detectable at both implant surfaces. (left) Oxidized surface. (right) Machined surface.



Day 1 observation

Day 1 biopsy specimens showed similar features as the day 0 specimens: very limited BIC (OS = 16.9%; MS = 12.9%), mainly restricted to the tip of the implant threads (Fig 5). No signs of ongoing new bone formation were evident, and no histologic differences were detectable at the two different surfaces.

Day 7 observation

At day 7, all specimens demonstrated active resorption of the bone chips and adjacent new bone formation (Fig 6). Intensive osteoblastic activity, shown by the high number of osteons, was evident around all of the residual bone chips with osteoid deposition. When the bone chips were close to the implant, new bone forma-

tion was evident in contact with the implant surface regardless of the roughness and morphology of the surface. On both surfaces, very little bone-forming activity was detectable where bone chips were not present.

The BIC values were still very low (OS = 23.5%; MS = 24.9%) and limited to the coronal cortical bone and the tips of the implant threads.

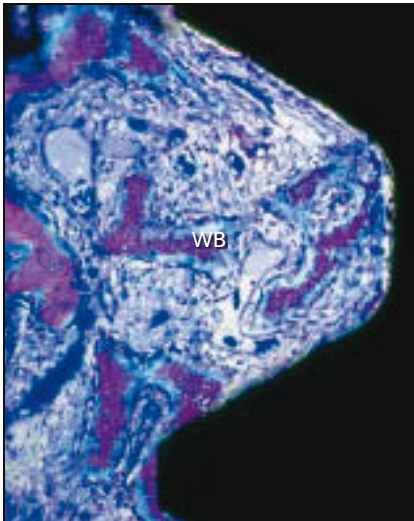


Fig 7 Histologic specimens at day 15 (original magnification $\times 20$). The residual bone chips appear extensively resorbed and have been substituted with woven bone (WB) surrounded by osteoid and an osteoblast layer. (left) Oxidized surface. (right) Machined surface.

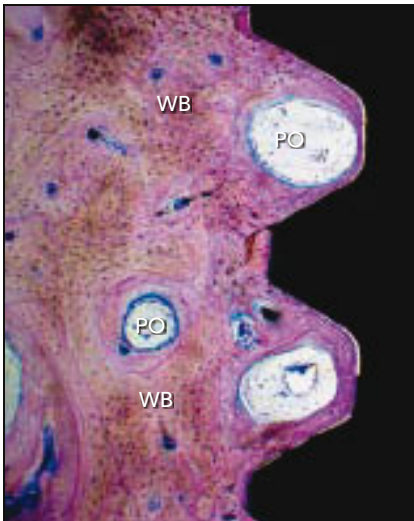
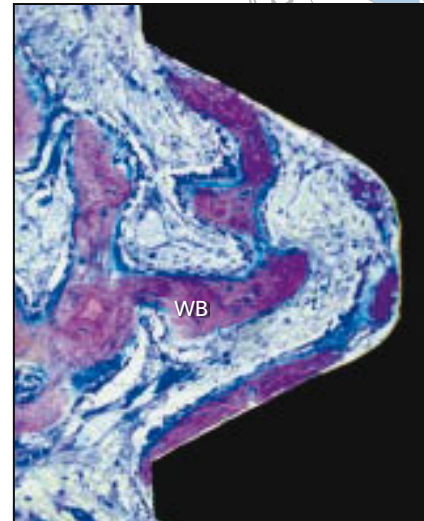
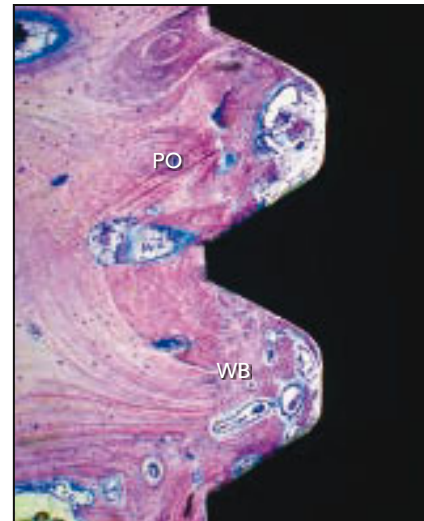

Fig 8 Histologic specimens at day 30 (original magnification $\times 10$). Newly formed woven bone (WB) is evident in all of the specimens regardless of the implant surface. Some early and immature primary osteons (PO) were visible. (left) Oxidized surface. (right) Machined surface.



Day 15 observation

The bone-forming activity was more pronounced in all of the specimens, and no qualitative or quantitative differences were detectable between the two different surfaces. The residual bone chips were almost completely resorbed and substituted with islands of woven bone surrounded by osteoid and an os-

teoblast layer (Fig 7). The new bone was often visible in contact with the implant surface.

The BIC values were still very low (OS = 26.9%; MS = 24.9%).

Day 30 observation

A large representation of newly formed woven bone was evident

in all of the specimens regardless of the implant surface. Intensive osteoblastic activity was still present in several bone remodeling units, indicating maturation of the woven bone to lamellar bone. Some early and immature primary osteons were visible in all specimens (Fig 8). Empty spaces were present between the implant threads in some areas, with

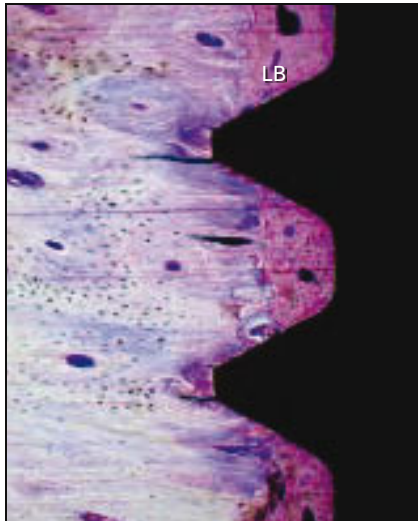
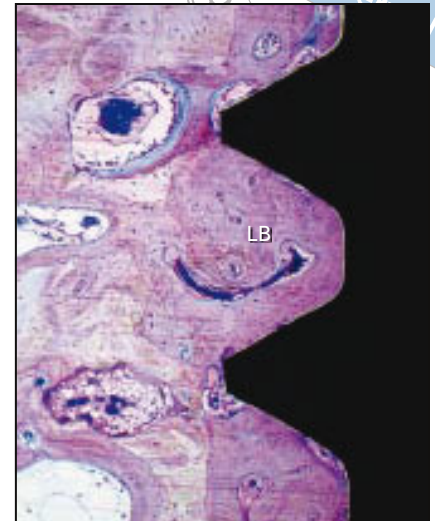


Fig 9 Histologic specimens at day 90 (original magnification $\times 10$). Mature lamellar bone (LB) is detectable close to the implant surface in all specimens. (left) Oxidized surface. (right) Machined surface.



bone formation proceeding from the native bone at a distance from the implant surface.

The BIC values substantially increased at both surfaces (OS = 42.5%; MS = 38.9%).

Day 90 observation

Mature lamellar bone was detectable close to the implant surface in all specimens (Fig 9). The qualitative and quantitative observation did not show any substantial difference between the surfaces (BIC, OS = 41.7%; MS = 48.6%).

Bone-forming activity appeared strongly reduced, and large amounts of primary osteons were present in the newly formed bone.

Discussion

The clinical success of oral implants is related to their early osseointegration, defined as a direct BIC without an intervening connective tissue

layer.^{7,8} The authors define early osseointegration as the time lapse between baseline (implant insertion) and 15 days. This study analyzed the new bone formation pattern at the bone-implant interface and the BIC of two dental implants differing in surface morphology and roughness at different times of healing: immediately after placement and after 1 day, 7 days, 15 days, 1 month, and 3 months. A single-stage technique with transgingival healing abutments was used to include a certain degree of loading in the model (there was no occlusal load, but load from the food bolus). The pattern of bone healing demonstrated the same features at the oxidized moderately rough surface and at the machined surface. The gaps between the implant surface and the native bone were initially filled with a blood clot containing erythrocytes and a high proportion of residual bone chips entrapped in a fibrin network.

The study demonstrated low BIC for both implant surfaces (OS

and MS) during the first 15 days after implant placement, ranging from 12.9% to 26.9% irrespective of the implant surface. Increased BIC values could be observed only in the 30-day specimens (OS = 42.5%; MS = 38.9%) and the 90-day specimens (OS = 41.7%; MS = 48.6%).

Osteoblastic activity was detectable in the 7- and 15-day specimens starting from the residual bone chip degradation and independent of the implant surface characteristics. The presence and degradation of residual bone chips acted as centers for new bone formation with osteoblasts lining osteoid tissue and subsequently woven bone. When the new bone-forming centers were close to the implant surface at a distance from the native bone, woven bone was found at the implant surface regardless of the roughness characteristics (distance osteogenesis).⁹ In contrast, when the residual bone chips were not present at the bone-implant interface, new bone formation appeared to progress

from the native bone to the implant surface (appositional bone formation).⁹ This finding is in accordance with a recent study from Nevins et al¹⁰ demonstrating higher BIC values when self-cutting implants were inserted in sites prepared to the minimum diameter of the implant, allowing the bone chips to be deposited into the cutting features and displaced apically.

The bone-forming activity appeared strongly reduced after 30 days of healing and seemed to be complete only in the 90-day specimens, where abundant lamellar bone was evident.

Most dental implants are made from grade 4 cpTi because it is stronger than other grades. There is a continuing effort to develop improved titanium surfaces to achieve more rapid osseointegration and improve the BIC. The ultimate goal is to apply occlusal load as soon as possible. This would offer a potential reduction in chair time and the associated cost of treatment.

Since immediate or early implant loading is considered to be applied during and not after the first 15 days after implant placement, the findings in the present study of an extremely low BIC and limited mineralized bone formation for both implant surfaces (OS and MS) during the first 15 days after implant placement suggest that the surface roughness does not seem to be a key factor for successful osseointegration of immediately or early loaded implants.

This is in accordance with the results of early clinical studies on immediate loading demonstrating

high success rates of machined implants placed in totally and partially edentulous patients. Calandriello et al presented a survival rate of 98% in 26 patients consecutively treated with 50 machined surface implants supporting 30 fixed partial dentures.¹¹ Similar results were presented by Vanden Bogaerde et al and Maló et al in partially edentulous patients.^{12,13} Maló et al¹⁴ also presented the first study of the all-on-four technique, which considered 44 totally edentulous patients treated with 176 machined implants in the mandible with a survival rate of 96.8%.

Roughened surfaces have been considered to be more conducive to osteoblast differentiation and therefore osseointegration and have led to a variety of grit-blasting and acid-etching techniques aimed at optimizing these properties.^{3,15} Various biomimetic coatings such as tricalcium phosphate and hydroxyapatite also have been used in an attempt to replicate the composition of the hydroxyapatite environment found in bone. The aim was to encourage osseointegration, but they were discontinued due to the high incidence of peri-implantitis.¹⁶

There is a difference of opinion related to whether osteoblast differentiation is increased by surface roughness.^{17–20} Some reports provide contradictory evidence suggesting that osteoblast differentiation is unaffected^{21–23} or reduced.^{24,25}

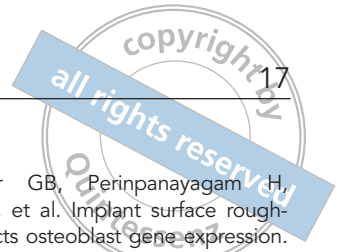Abrahamsson et al²⁶ reported similar bone-healing characteristics with resorptive and appositional events for sandblasted, large-grit,

acid-etched, and turned surfaces, but the rate and degree of osseointegration were superior for the sandblasted, large grit, acid-etched than for the turned surface, despite the fact that the amount of lamellar bone was much higher in the turned surface at 6, 8, and 12 weeks after implant placement.

Kawahara et al²⁷ reported no differences when comparing BIC of blast-roughened surfaces to machined surfaces in the canine mandible after 6 or 24 weeks. Similarly, it has been reported that blasting with titanium oxide grit, ceramic grit, or acid etching had no effect on the histologic formation of bone around implants placed in the canine mandible after 1 or 3 weeks.²⁸ A recent study monitored the bone-healing process around titanium alloy implants with modified surface topography and chemistry in fresh extraction sockets in rats.²³ The authors reported that these implant surface modifications had no influence on the activity of bone-forming cells surrounding the implant in time frames of 1, 3, and 9 weeks.

Conclusions

Within the limits of this study, including its limited number of subjects, it can be stated that osseointegration follows the same healing pattern at machined and oxidized implant surfaces. In particular, both the rate of osseointegration and the degree of BIC over 3 months was independent of the characteristics of the tested implant surfaces.



Acknowledgments

The authors reported no conflicts of interest related to this study.

References

- Gottlow J, Barkarmo S, Sennerby L. An experimental comparison of two different clinically used implant designs and surfaces. *Clin Implant Dent Relat Res* 2012;14(suppl 1):e204–e212.
- Colombo JS, Satoshi S, Okazaki J, Crean SJ, Sloan AJ, Waddington RJ. In vivo monitoring of the bone healing process around different titanium alloy implant surfaces placed into fresh extraction sockets. *J Dent* 2012;40:338–346.
- Le Gue'hennec L, Soueidan A, Layrolle P, Amouriq Y. Surface treatments of titanium dental implants for rapid osseointegration. *Dent Mater* 2007;23:844–854.
- Astrand P, Engquist B, Anzén B, et al. A three-year follow-up report of a comparative study of ITI Dental Implants and Brånemark System implants in the treatment of the partially edentulous maxilla. *Clin Implant Dent Relat Res* 2004;6:130–141.
- Carcuac O, Abrahamsson I, Albouy J-P, Linder E, Larsson L, Berglundh T. Experimental periodontitis and peri-implantitis in dogs. *Clin Oral Implants Res* 2013;24:363–371.
- Berglundh T, Gotfredsen K, Zitzmann NU, Lang NP, Lindhe J. Spontaneous progression of ligature induced peri-implantitis at implants with different surface roughness: An experimental study in dogs. *Clin Oral Implants Res* 2007;18:655–661.
- Albrektsson T, Brånemark PI, Hansson HA, Lindstrom J. Osseointegrated titanium implants. Requirements for ensuring a long-lasting, direct bone-to-implant anchorage in man. *Acta Orthop Scand* 1981;52:155–170.
- Davies JE. Understanding peri-implant-endosseous healing. *J Dent Educ* 2003;67:932–949.
- Davies JE. Mechanisms of endosseous integration. *Int J Prosthodont* 1998;11:391–401.
- Nevins M, Nevins M, Schupbach P, Fiorellini J, Lin Z, Kim D. The impact of bone compression on bone-to-implant contact of an osseointegrated implant: A canine study. *Int J Periodontics Restorative Dent* 2012;32:637–645.
- Calandriello R, Tomatis M, Rangert B. Immediate functional loading of Brånemark System implants with enhanced initial stability: A prospective 1- to 2-year clinical and radiographic study. *Clin Implant Dent Relat Res* 2003;5(suppl 1):10–20.
- Vanden Bogaerde L, Pedretti G, Dellacasa P, Mozzati M, Rangert B. Early function of splinted implants in maxillas and posterior mandibles using Brånemark system machined-surface implants: An 18-month prospective clinical multicenter study. *Clin Implant Dent Relat Res* 2003;5(suppl 1):21–28.
- Maló P, Friberg B, Polizzi G, Gualini G, Vighagen T, Rangert B. Immediate and early function of Brånemark implants placed in the esthetic zone: A 1-year prospective clinical multicenter study. *Clin Implant Dent Relat Res* 2003;5(suppl 1):37–46.
- Maló P, Rangert B, Nobre M. "All-on-four" immediate function concept with Branemark System implants for completely edentulous mandibles: A retrospective clinical study. *Clin Implant Dent Relat Res* 2003;5(suppl 1):2–9.
- Zhao G, Schwartz Z, Wieland M, et al. High surface energy enhances cell response to titanium substrate microstructure. *J Biomed Mater Res A* 2005;74:49–58.
- Daculsi G, Laboux O, Malard O, Weiss P. Current state of the art of biphasic calcium phosphate bioceramics. *J Mater Sci Mater Med* 2003;14:195–200.
- Castellani R, de Ruijter A, Renggli H, Jansen J. Response of rat bone marrow cells to differently roughened titanium discs. *Clin Oral Implants Res* 1999;10:369–378.
- Wall I, Donos N, Carlqvist K, Jones F, Brett P. Modified titanium surfaces promote accelerated osteogenic differentiation of mesenchymal stromal cells in vitro. *Bone* 2009;45:17–26.
- Schneider GB, Perinpanayagam H, Clegg M, et al. Implant surface roughness affects osteoblast gene expression. *J Dent Res* 2003;82:372–376.
- Boyan BD, Lössdorfer S, Wang L, et al. Osteoblasts generate an osteogenic microenvironment when grown on surfaces with rough microtopographies. *Eur Cell Mater* 2003;6:22–27.
- Setzer B, Bachle M, Metzger MC, Kohal RJ. The gene expression and phenotypic response of hFOB 1.19 osteoblasts to surface-modified titanium and zirconia. *Biomaterials* 2009;30:979–990.
- Annunziata M, Oliva A, Basile MA, et al. The effects of titanium nitride-coating on the topographic and biological features of TPS implant surfaces. *J Dent* 2011;39:720–728.
- Colombo JS, Satoshi S, Okazaki J, Crean SJ, Sloan AJ, Waddington RJ. In vivo monitoring of the bone healing process around different titanium alloy implant surfaces placed into fresh extraction sockets. *J Dent* 2012;40:338–346.
- Ter Brugge PJ, Wolke JG, Jansen JA. Effect of calcium phosphate coating crystallinity and implant surface roughness on differentiation of rat bone marrow cells. *J Biomed Mater Res* 2002;60:70–78.
- Colombo JS, Carley A, Fleming GJ, Crean SJ, Sloan AJ, Waddington RJ. Osteogenic potential of bone marrow stromal cells on smooth, roughened, and tricalcium phosphate-modified titanium alloy surfaces. *Int J Oral Maxillofac Implants* 2012;27:1029–1042.
- Abrahamsson I, Linder E, Lang NP. Implant stability in relation to osseointegration: An experimental study in the Labrador dog. *Clin Oral Implants Res* 2009;20:313–318.
- Kawahara H, Aoki H, Koike H, Soeda Y, Kawahara D, Matsuda S. No evidence to indicate topographic dependency on bone formation around cp titanium implants under masticatory loading. *J Mater Sci Mater Med* 2006;17:727–734.
- Coelho PG, Granato R, Marin C, et al. Biomechanical evaluation of endosseous implants at early implantation times: A study in dogs. *J Oral Maxillofac Surg* 2010;68:1667–1675.